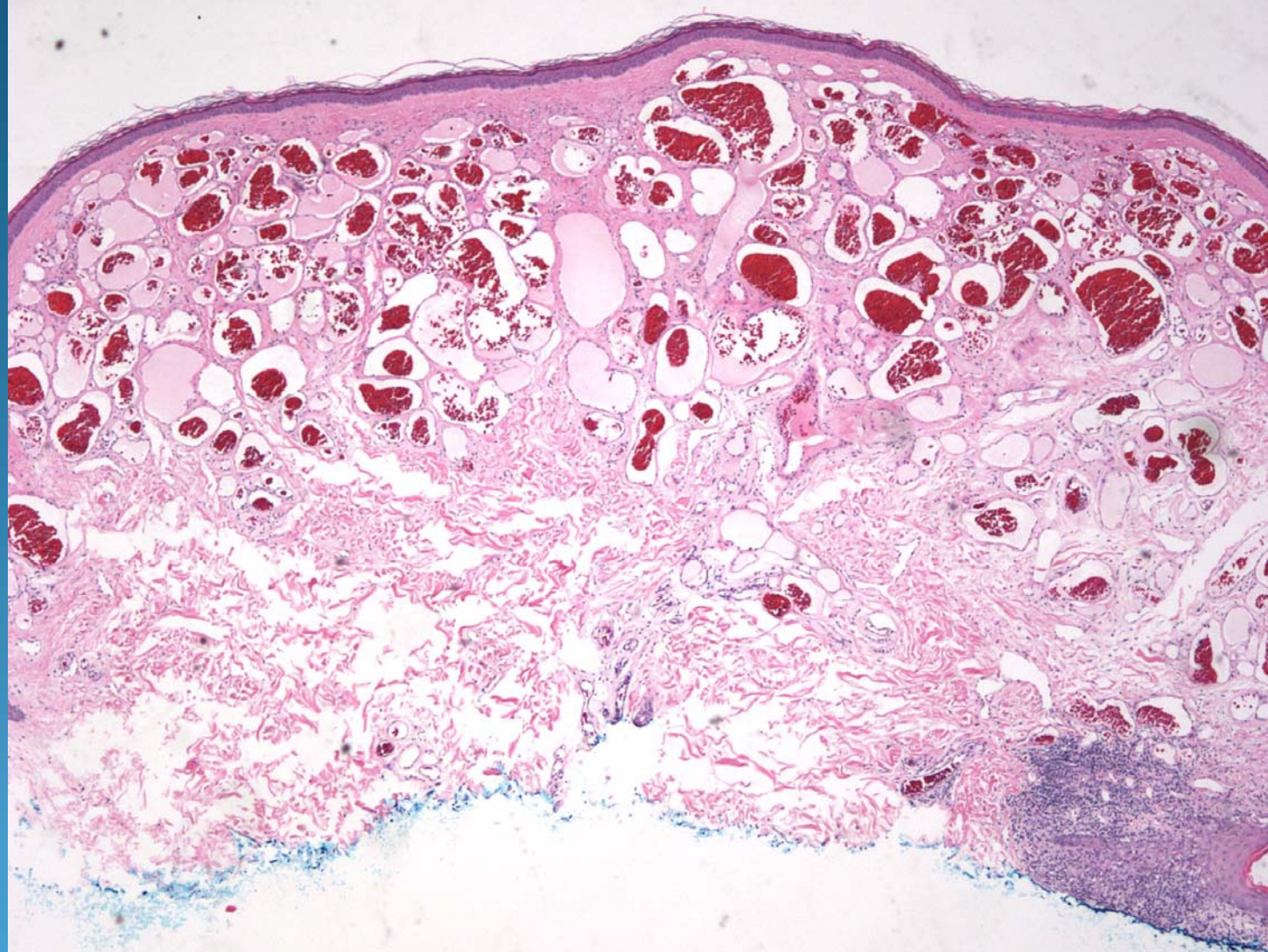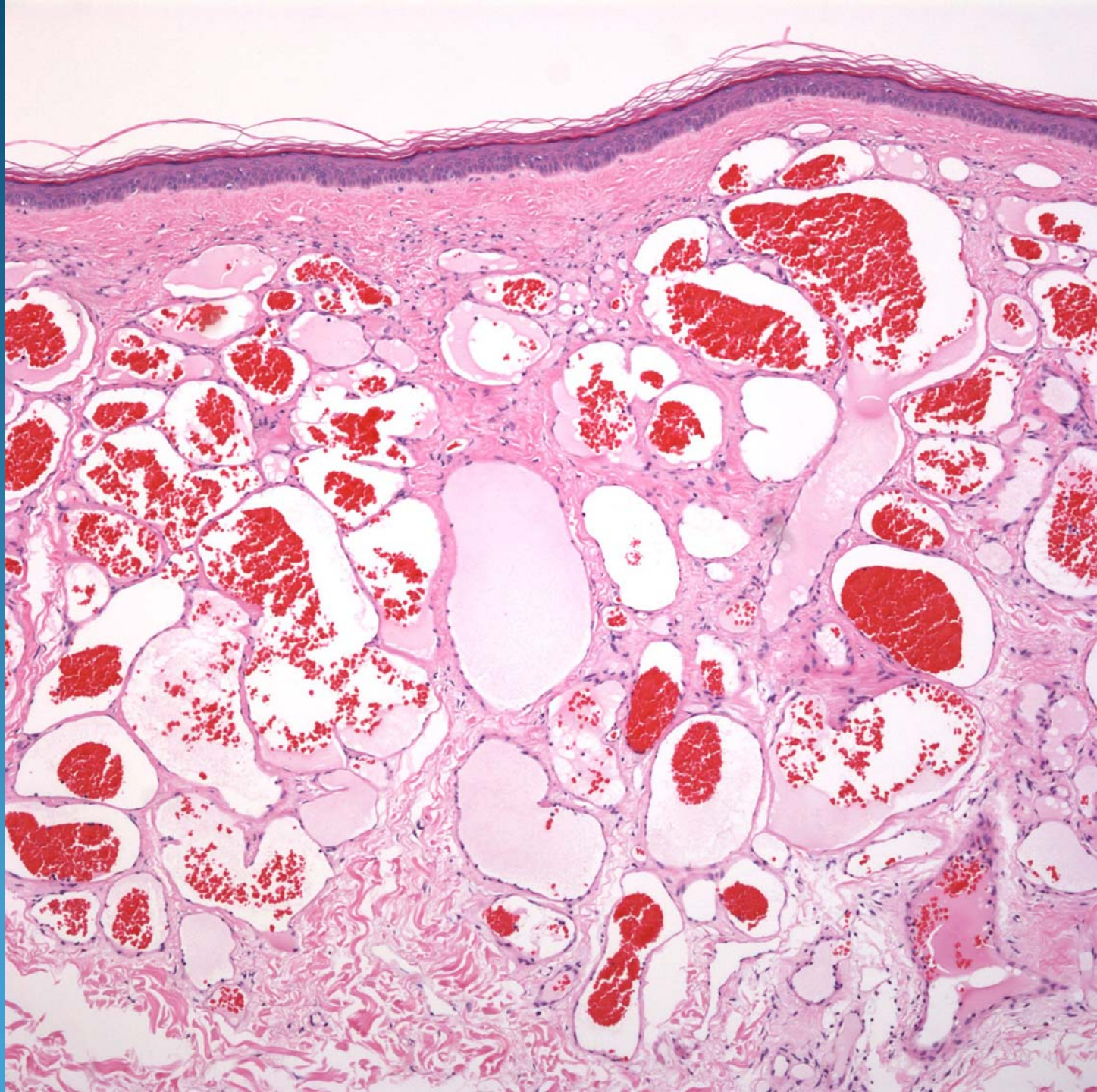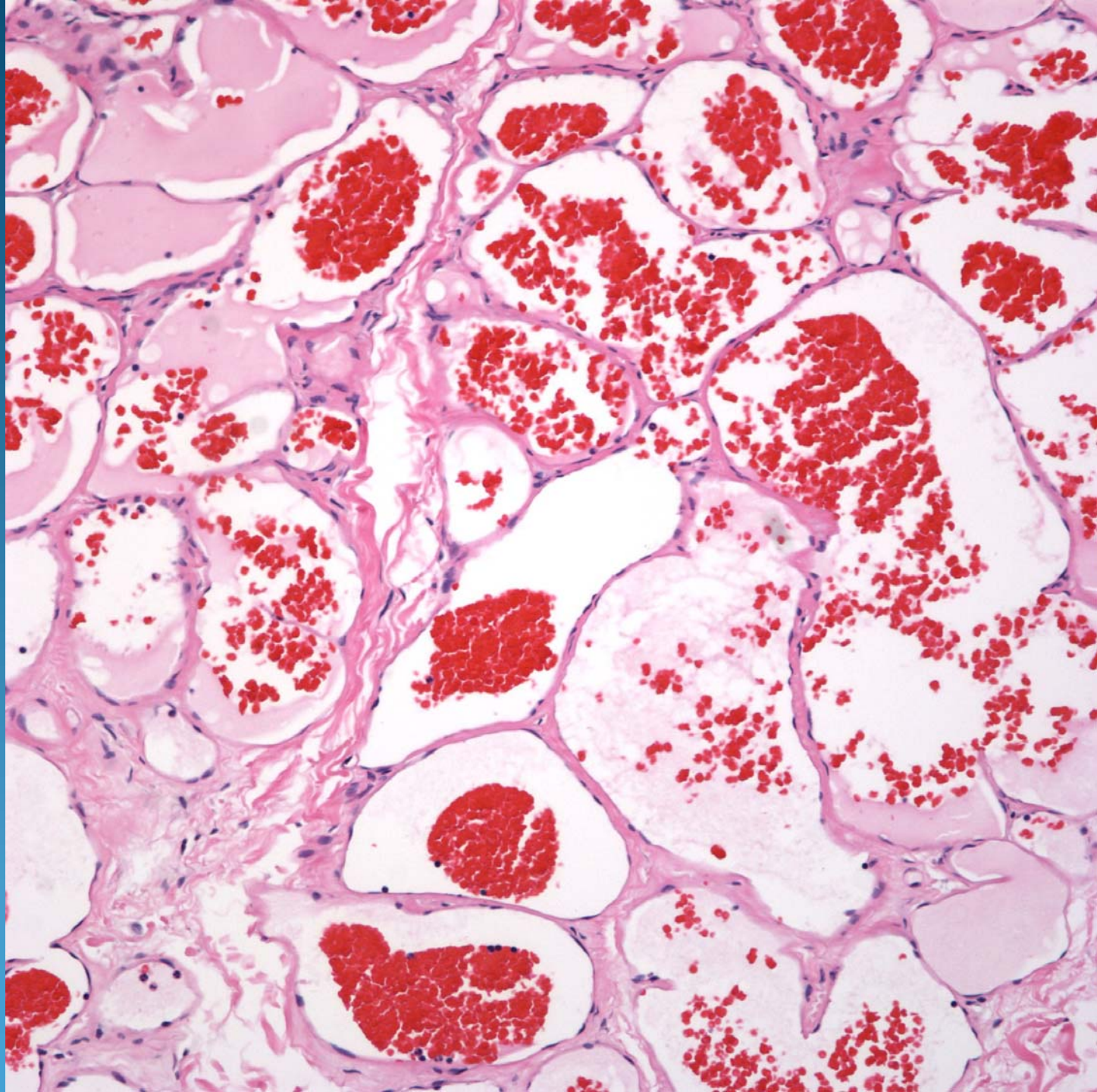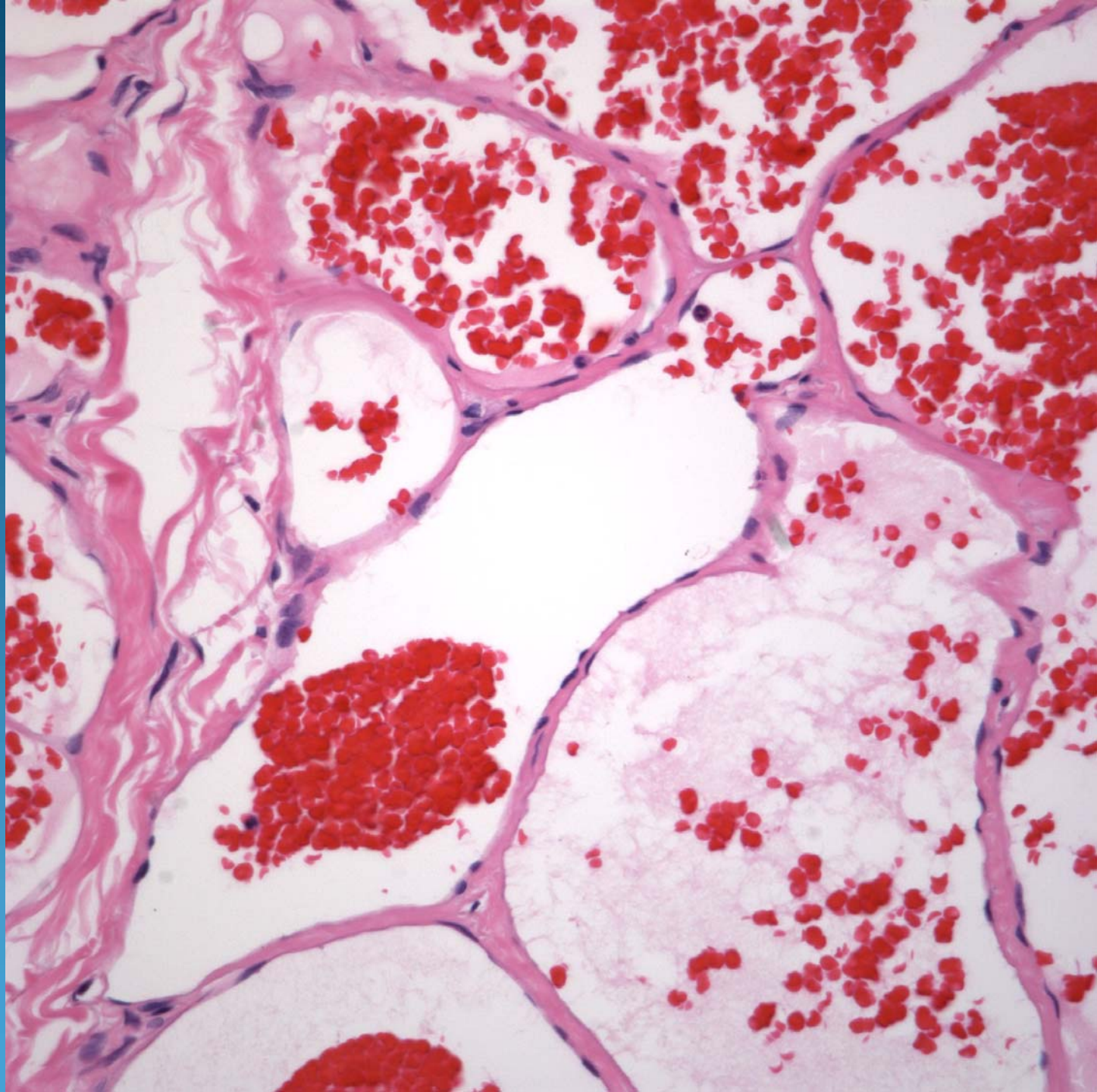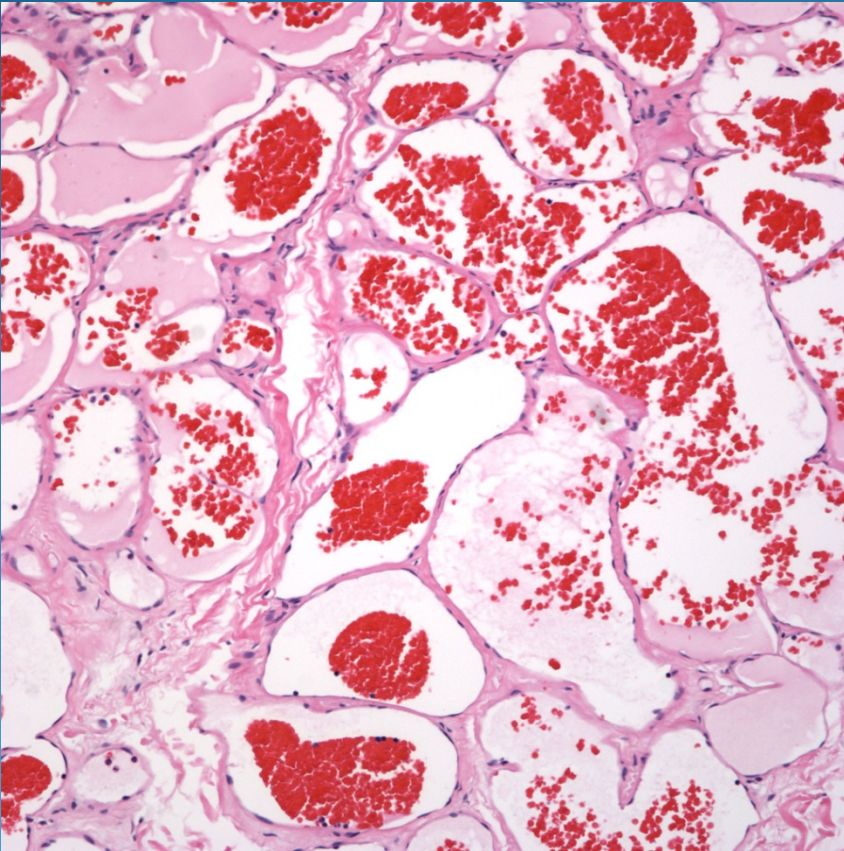


# Hemangioma

# Pearls



- Thin-walled vascular spaces lined by bland endothelial cells
- Lumen often distended with rbc
- Secondary thrombosis common